

# Veterinary Viewpoints

N. Y. S. COLLEGE OF  
VETERINARY MEDICINE

NOV 15 1983

FLOWER LIBRARY

The New York State College of Veterinary Medicine at Cornell University

Fall 1983


## CORNELL'S FIRST GERM-FREE CALF SURGICALLY DERIVED AT SPF UNIT

There were no cigars, no pink or blue booties, and mom was more interested in getting back to the barn, nevertheless it was a birth to remember. It was Cornell's first germ-free calf, surgically delivered by veterinarians at the Bovine Research Center's Specific Pathogen Free (SPF) Unit. Dr. Donald Schlafer, Director of the Center and Assistant Professor at the New York State College of Veterinary Medicine, described how the calf was delivered by cesarean section in the unit's own surgical suite then passed through a germicidal bath to a specially designed germ-free isolator. This flexible-film bubble will be the newborn's home for the next several months.


Germ-free calves are vital to many modern research projects requiring animals free of the disease causing bacteria, viruses and other microbes present in conventionally reared animals. The Bovine SPF Unit in


Cornell's Bovine Research Center is one of only a few facilities in the world specialized in the derivation and maintenance of these calves. The unit contains an animal surgery room, preparation and nursery room, two isolator holding rooms and support areas. Each of its two holding rooms will accommodate 12 specially designed flexible film sterile isolators with one calf per isolator. Construction of the SPF Unit was made possible through the contributions of dairymen, agricultural industries, professional associations and private foundations.

Faculty members of the New York State College of Veterinary Medicine and the College of Agriculture and Life Sciences at Cornell will utilize the germ-free calves in many areas of cattle research, particularly in work focusing on infectious and metabolic diseases.



(Above right) Cornell's first SPF calf born August 2, 1983. (Right) Dr. Lloyd Dillingham, Director of Laboratory Operations, checks the calf's progress through one of the glove ports in the flexible film isolator.





## **DR. GEOFFREY SHARP NAMED DIRECTOR OF CORNELL'S DIVISION OF BIOLOGICAL SCIENCES."**

Dr. Geoffrey W. G. Sharp, chairman of the Department of Pharmacology in the New York State College of Veterinary Medicine, Cornell University, has been named director of the Division of Biological Sciences at Cornell University. Dr. Sharp will continue to serve as Chairman of the Department of Pharmacology.

A noted researcher in the fields of ion transport and insulin release, Dr. Sharp will assume his new duties on Oct. 1. Dr. Sharp replaces Dr. Robert Barker, who became vice president for research and advanced studies at Cornell on July 1.

Born and educated in England, Dr. Sharp received a Ph.D. in pharmacology from the University of Nottingham, and a D.Sc. from the University of London. While at the University of Nottingham, he led physiological expeditions in 1957 and 1960 to the Arctic settlement of Spitzbergen where he studied the effects of activity and light on circadian rhythms in man.

In 1962, he moved to the Massachusetts General Hospital and the Harvard Medical School to conduct research on the mechanisms of control of sodium transport, primarily on the actions of aldosterone and of antidiuretic hormone. He taught in the Departments of Pharmacology and of Physiology at Harvard Medical School and Biochemistry at Harvard College. He was chief of the Biochemical Pharmacology Unit at Massachusetts General Hospital from 1966 until 1978 when he joined the faculty of Tufts University as professor and chairman of the Department of Physiology in the Schools of Medicine, Dental Medicine and Veterinary Medicine. In 1980, he accepted the position of professor and chairman of the Department of Pharmacology at Cornell's College of Veterinary Medicine.

As a result of early studies of the cholera toxin, his work with aldosterone and antidiuretic hormones, and his role as consultant to the SEATO-PHS Hospital in Dacca Bangladesh, Dr. Sharp's research has most recently involved the investigation of pharmacological agents effective in the treatment of severe diarrheal disease. A year's sabbatical leave at the Institute of Clinical Biochemistry at the University of Geneva, Switzerland, also developed a long-term interest in diabetes-related research. Using a blend of pharmacological, biochemical and physiological teachings, Dr. Sharp is studying control mechanisms of hormone synthesis and release in the pancreas.

Dr. Geoffrey Sharp's eclectic expertise and interests will complement the Division of Biological Sciences' six sections of Biochemistry, Molecular and Cell Biology, Ecology and Systematics, Genetics and Development, Neurobiology and Behavior, Physiology, and Plant Biology. The L.H. Bailey Hortorium and the Shoals Marine Laboratory will also be under his direction.

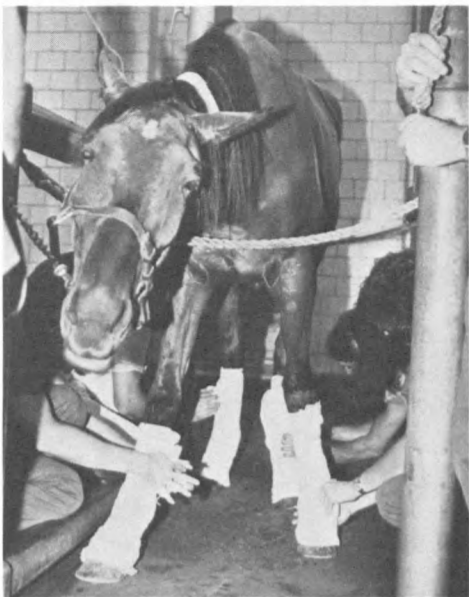### **Veterinary Viewpoints**

Veterinary Viewpoints is published four times a year for friends and alumni of the New York State College of Veterinary Medicine, a Statutory College of the State University of New York. Correspondence may be addressed to Karen Redmond, Editor, Schurman Hall, New York State College of Veterinary Medicine, Cornell University, Ithaca, New York 14853. Telephone: 607/256-5454.

Cornell University is an equal opportunity, affirmative action educator and employer.



## THE TRAUMA OF EQUINE COLIC FROM ADMISSION TO RECOVERY



A 3-year old racing Standardbred gelding was presented with a history of colic for 5 days. The local veterinarian's rectal examination of the horse indicated a probable impaction. Despite medical treatment, the colic persisted, and the patient was referred to the New York State College of Veterinary Medicine.



**2:30 p.m.** The patient is admitted to the Large Animal Clinic of New York State College of Veterinary Medicine, and led directly to the Treatment room where Dr. David Bristol, surgery resident, is waiting.

**2:36** Dr. Bristol begins the physical examination. The patient's extremities are normal in temperature. Mucous membranes are bright pink. Visual examination shows slight abdominal distention on the right side. Gut sounds are decreased and the patient suffers from intermittent severe pain.

Blood is drawn and sent to the laboratory for a complete blood count (CBC), and an analysis of blood gases and electrolytes.

**2:38** Students begin clipping the hair over the jugular vein for a catheter, and on the ventral midline for a peritoneal tap. Other students record examination data and patient history, assign a case number and enter a pharmacy account.

Dr. Richard Hackett, chief of service, examines the patient. Drs. Bristol and Hackett discuss the patient's condition and probable treatment.

**2:39** Despite a mild sedative administered on admission, colic makes the patient kick and paw in the stocks. It is becoming difficult to clip or examine the patient.

**2:40** In severe pain now, the patient attempts to lie down in the stocks. Xylazine is given to ease the pain. Its effects should last from 30 minutes to 1 hour.

**2:41** A nasogastric tube is passed to relieve fluid and gaseous distention. Less than 1 liter of green fluid is drained.

**2:45** Preparations are completed for abdominal paracentesis, or the peritoneal tap. A site has been clipped and scrubbed on the ventral midline.

**2:49** Drs. Hackett and Bristol complete a rectal palpation of the horse. All palpable structures are evaluated including the cecum, large and small colon, small intestine, and other organs. They confirm the referring veterinarian's finding of a distention of the pelvic flexure and left colon. These structures are displaced toward the midline.



2:55


**2:55** A needle is passed through the body wall into the peritoneal cavity. This abdominal tap produces 2-3 ml. of cloudy yellow liquid. Yellow turbid fluid might indicate diffuse peritonitis. Amber indicates an infarction of the bowel by thromboembolism or strangulation. Reddish-brown may mean a rupture of a viscus. The fluid is sent to the Cytology laboratory where the number, and types of cells in the fluid will be analysed.

**2:56** A catheter is placed in the jugular vein, and fluid and electrolyte replacement begins.

**3:06** The blood work is back from the laboratory. Results are unremarkable but because of the patient's severe pain, and abnormal rectal findings, surgical treatment is recommended.

**3:15** The clients are informed of the decision. Dr. Hackett explains the procedure and why surgery is necessary.

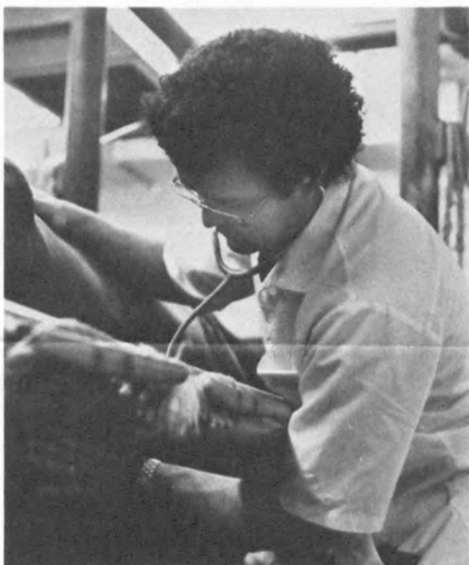**3:35** Client permission is given for surgery.



2:56



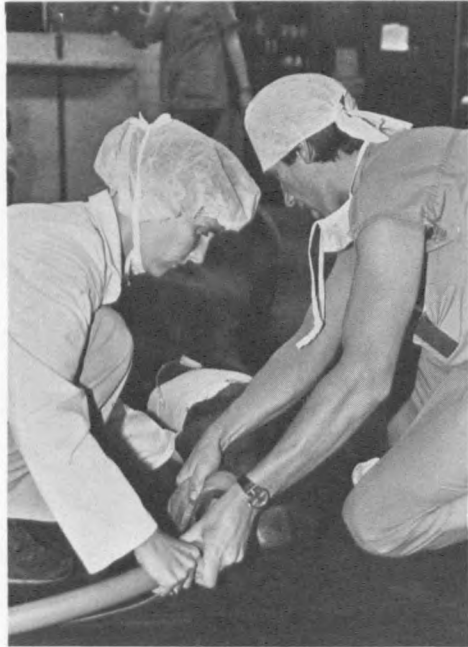3:06



2:38



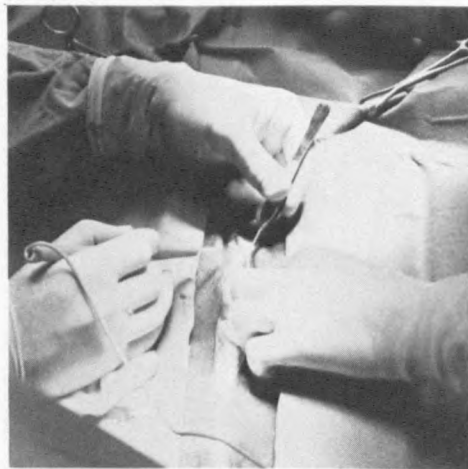
2:41



4:01



4:06



4:24

4:36

**3:40** Surgical staff have been aware that colic surgery may be necessary, and now final preparations are made. Surgical supplies in their sterile packets are readied. The anesthesiology crew assembles. Dr. Robin Gleed, anesthesiologist, has already evaluated the condition of the patient in the treatment room. Technicians and students begin assembling equipment and instruments while the patient is led into the surgery.

**AT THIS TIME A SECOND COLIC CASE IS ADMITTED TO THE LARGE ANIMAL CLINIC. AFTER EXAMINATION, MEDICAL TREATMENT IS RECOMMENDED.**

**3:55** A preanesthetic medication is administered to quiet the patient.

**4:00** The anesthetic is injected.

**4:01** The patient is down. Surgery technicians finish clipping the abdomen. Anesthesiology crew inserts a speculum into the mouth, preliminary to passing an endotracheal tube into the trachea. Until the operation is over, the patient will breathe a mixture of gas and oxygen that will keep him heavily anesthetized. Heart, respiratory rate and blood pressures will be continuously monitored until the surgery is over.

**4:02** The surgery table has been moved into the room. In a group effort, the patient is pulled on top of it.

As the table is raised to operating height, side boards are attached and the patient is positioned in dorsal recumbency. Clipped hair is vacuumed away and the abdomen is repeatedly scrubbed with Betadine solution and rinsed with alcohol.

Already wearing footgear and in caps and surgical masks, Drs. Hackett, Bristol and Hanson begin scrubbing for surgery. Dr. Hackett as chief surgeon will direct the operation, assisted by Dr. Bristol, surgery resident, and Dr. Hanson, surgery intern.

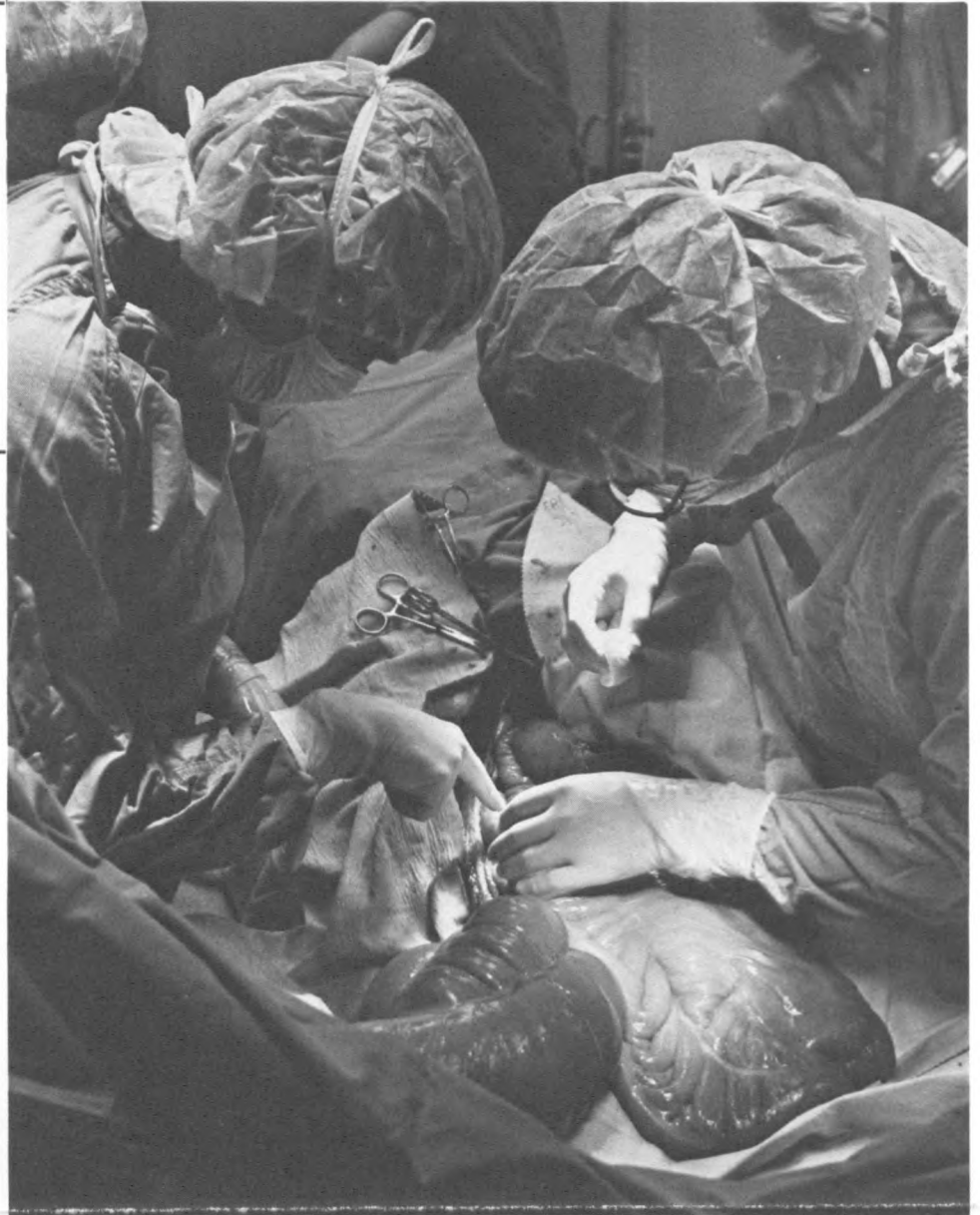**4:06** Surgical prepping continues and final positioning of the patient is completed.

**4:10** Students and nursing staff position monitors, surgical trays, surgical lights, the suction and cautery machine around the table.

**4:12** The three veterinarians don surgical gowns and gloves. Everyone in the surgery room must now wear head covers, a mask and surgical greens or a gown.

**4:16** The surgeons completely drape the patient with sterile drapes, leaving only the ventral midline exposed.

**4:24** The abdominal incision is made.



**4:25** Gas is removed from a section of bowel by a needle and mechanical suction.

**4:26** The puncture site is closed with a suture.

**4:36** Surgeons exteriorize parts of the colon and cecum. It becomes obvious that the large colon is displaced and that a damaged section of the colon wall has suffered a full thickness tear. This is repaired after impacted feed material is removed through an incision near the pelvic flexure.

**5:40** The bowel is now empty of impacted feed material and gas. Surgeons check the bowel for additional damaged or displaced areas.

**5:45** Abdominal lavage with warm isotonic fluid follows. The bowel is replaced.

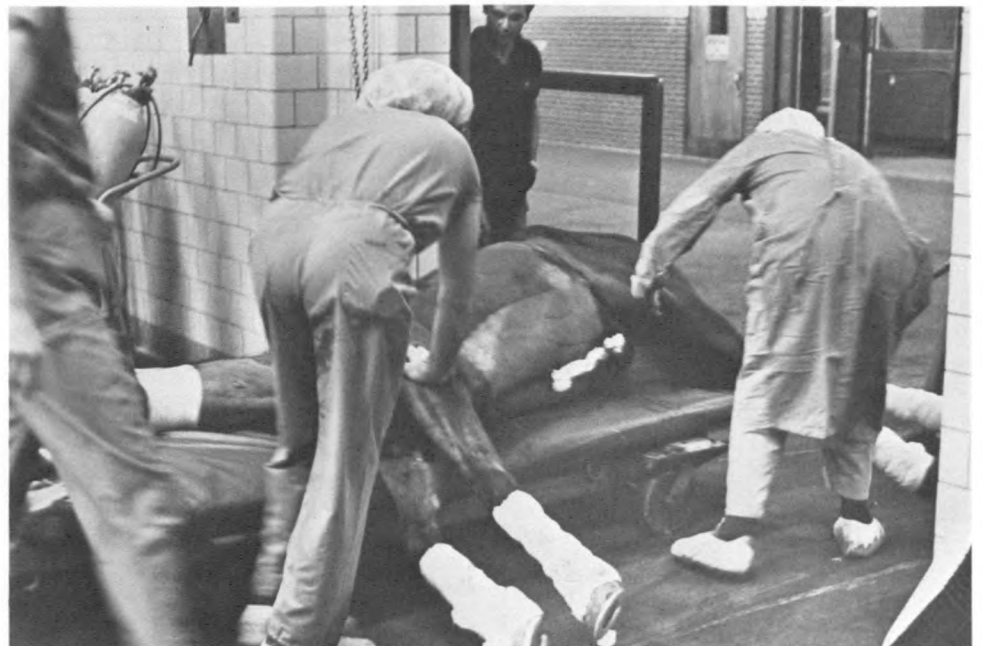**5:50** They're beginning to close. Drs. Hackett and Bristol begin at opposite ends of the incision and work towards the middle.

**6:10** They've finished closing. Anesthesia is discontinued, the side boards are removed, the table lowered and the patient is wheeled to the padded recovery room.

**6:25** The patient is beginning to come out of anesthesia.

**6:30** The patient is extubated—the anesthesia tube and speculum are removed.

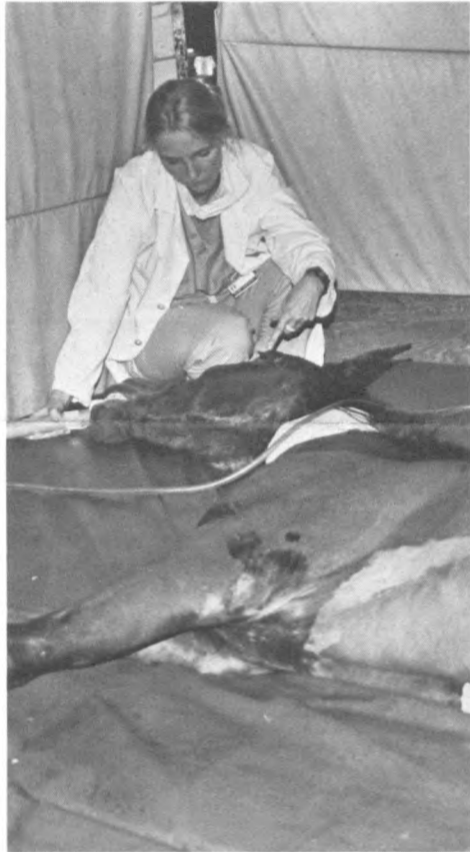6:10





## EQUINE COLIC: A FEW WHAT, WHERE, WHY & HOWS

By 8:15 p.m., this patient is standing and has been moved to a box stall. Intravenous fluids, antibiotics and analgesic drugs are continued and the horse was monitored carefully. His recovery following surgery was excellent and he was discharged from the hospital two weeks later.



6:25

While veterinarians waited for this case to recover from anesthesia, a telephone call notified the clinic that another colic case was on its way. This patient was admitted at 9:15 that evening, and because of the extreme severity of the colic, went immediately to surgery. Surgeons worked for three hours to save the horse, but nothing could be done to correct a large intestinal torsion or to repair large sections of devitalized bowel. The horse was euthanized while still under anesthesia.

### WHAT IS IT?

Colic is an all-encompassing term used for acute abdominal disease. This disease may, in turn, be broken down into several types. *Functional colic*, which includes spasmodic, "impaction-type", and flatulent colic, arises from impairment of gastrointestinal function while structure remains intact. These are the majority of colic cases and ordinarily respond to medical treatment.

"Simple" intestinal obstruction, is another form of colic. "Simple" does not rule out life-threatening, however, because the resulting dehydration, electrolyte loss and shock are significant dangers. Obstructions may be impactions from feedstuffs, intestinal strictures, adhesions, tumors or abscesses. Surgeons occasionally find intestinal calculi formed by layers of mineral salts around an indigestible foreign body. Called enteroliths, they can be as large and round as a bowling ball.

In colic caused by the *strangulation obstruction of intestine* there is a compromise of the blood supply to the bowel, with or without a similar compromise of its interior structure. Examples of this class of colic are a strangulated hernia, a section of intestine telescoping on itself, a twist in the intestine, or loss of blood supply due to bloodworms (*Strongylus vulgaris*).

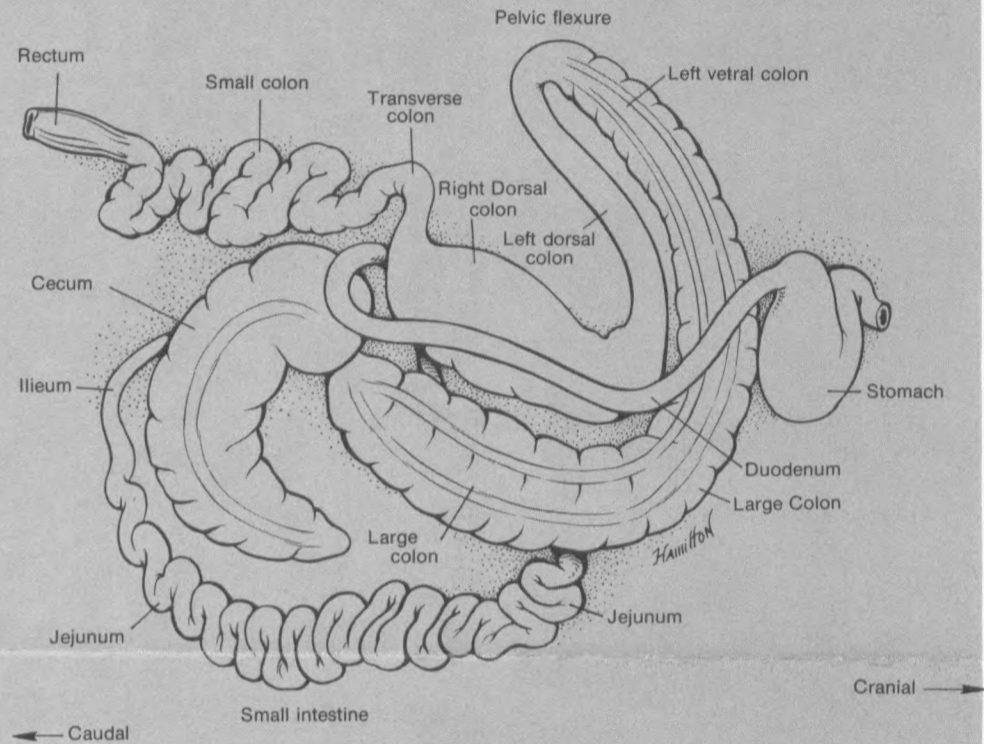
Horses showing severe pain with distention of the stomach with fluid and/or gas have yet another form of colic — *gastric dilation or rupture*. Primary gastric dilation may be caused by grain overload, or the presence of tumors, ulcers or parasites at the closure of the stomach. Rupture of the stomach from gastric dilation may occur. After the rupture, the animal in severe pain will appear to be comfortable, but there is rapid deterioration of the cardiovascular system and death follows.

Not all colic pain originates in the digestive tract. Abdominal pain may be caused by abnormalities of the ovaries, uterus or bladder.

### HOW DO YOU TREAT COLIC?

A large number of colics will respond to medical treatment. The veterinarian will use drugs to control pain or spasms, increase gut motility or reduce bacterial fermentation in the gut. Fluid and gastric distention can be relieved by passing a nasogastric tube or passage of a needle through the body wall into the distended bowel. Called a trocharization, this should only be performed by a veterinarian.

Impactions by feedstuffs may be softened with mineral oil and other lubricants. In other cases, an enema or systemic antibiotics will be indicated. Antihistamines, may be recommended if the colic is caused by a



Schematic Diagram of the Gastrointestinal Tract of the Horse

grain overload. Volume and electrolyte replacement is necessary in some instances, while laboratory blood tests monitor metabolic balance.

Horses whose colic does not respond to medical treatment are considered surgical colics. Generally, these are cases of strangulation obstruction, simple obstruction with progressive deterioration of metabolic parameters or a colic that is unresponsive to conservative medical therapy. The earlier a surgical case is identified, the greater the likelihood of a successful surgical intervention.

Some colics are considered inoperable. These are cases where a rupture or perforation of the bowel soils the peritoneal cavity with digesta or in cases where the patient is in terminal shock.

### SURVIVAL: WHAT ARE THE CHANCES?

At present, the overall survival rate for surgical colics is approximately 60%. The survival for strangulation obstruction is 25% and that for simple obstruction (impaction) is over 80%. Survival rate, especially for strangulation obstruction, is directly related to the time span between onset and surgical intervention.

In a paper written on colic cases at the clinic, investigators found that "short term (after discharge) survival rate was 62.7% and the long term (over 7 months) survival rate was 45.5%. Horses with disorders affecting the small intestine or requiring intestinal resection had a significantly lower survival rate. Causes of death early in the postoperative period included long bone fracture, shock, ileus, gastric rupture and peritonitis. After discharge from the hospital, deaths were attributed to colic of unknown cause, malabsorption syndrome, adhesive small bowel obstruction, small and large intestinal volvulus, perforated bowel and laminitis. The overwhelming majority of horses that survived returned to previous use."\*

\* Ducharme, N.G., Hackett, R.P., Ducharme, G.R., Long, S., The Outcome of 181 Horses Surgically Treated For Colic: A Retrospective Study. Presented at the 17th Annual Meeting of the American College of Veterinary Surgeons, 1982.





## SORTING CELLS AT JAMES BAKER INSTITUTE

Finding a cellular needle in the biological haystack will be easier for Cornell researchers with the purchase of a fluorescence activated cell sorter and its accessories by the James A. Baker Institute for Animal Health. Part of the proposed Flow Cytometry Laboratory at the Institute, the cell sorter is integral to the work of Cornell scientists involved in preparative sorting or analysis of living cells, cell components, or particles. The instrument was funded by a grant of \$157,000 from the Department of Health & Human Services, Division of Research.

The Flow Cytometry Laboratory will operate as a central University resource, staffed and provisioned expressly for cell and particle sorting. As user demands increase, the versatility and efficiency of the laboratory's cell sorter would be enhanced by the addition of various operating accessories and data processing components. The entire laboratory will be maintained by a full-time specially trained electronics technician with costs defrayed by a uniform fee-for-service charge to all users.

The Baker Institute was founded in 1950 as a permanent facility for research and teaching on animal diseases. Scientists at the Institute continue to break new ground

in such areas as immune response to parasites, the role of genetic factors in susceptibility to disease, and the generation and use of monoclonal antibodies.

## AWARDS, GRANTS & FUNDING

DR. GEOFFREY W. SHARP, Department of Pharmacology, has received a grant of \$104,413 from the National Institute of Arthritis, Diabetes, Digestive & Kidney Diseases for the continuation of his studies on the role of calmodulin in the control of insulin release.

DR. DONALD G. LINDMARK, Department of Preventive Medicine, is the recipient of a World Health Organization (W.H.O.) grant. Funded under the W.H.O. parasitic disease program, the grant will support Dr. Lindmark's study on the "Biochemical Cytology of Giardia". *Giardia lamblia*, the cause of giardiasis in man and animals, is the most common intestinal protozoan parasite worldwide.

## AVIAN CLINIC HOME FOR BALD EAGLES

Three bald eagles took up involuntary residence in the Avian Clinic this fall. The raptors are part of the New York State release program that hopes to increase the breeding population of bald eagles statewide. Gene McCaffrey and Pete Nye at the New York State Department of Environmental Conservation sent the thirteen-week-old eagles to the Clinic after they developed nodular skin eruptions. On their arrival at the clinic, the fledglings were examined by Drs. David Graham and Christopher Murphy who identified the problem as a viral skin


infection. The illness delays the planned release of the bald eagles during warm weather and they are now scheduled for release into the wild in 1984.

In support of their work with wild birds, the Avian Clinic has received a \$500 donation from the North Shore Animal League of Long Island. A portion of the funds enabled student supervisors for the avian clinic to attend the 3rd Annual New York State Wildlife Rehabilitation Council meeting. The remaining money will be used to help offset operating expenses in the Avian Clinic.


## DR. ALILA WINS "YOUNG INVESTIGATOR AWARD"

Dr. Hector W. Alila, of the New York State College of Veterinary Medicine at Cornell, has received the "Young Investigator Award" from the Society for the Study of Reproduction. The award was made at the 16th annual meeting of the society at Case Western Reserve University in Cleveland, Ohio, August 9, 1983. A graduate student in Physiology, Dr. Alila was honored for his work entitled, "Origin of Different Cell Types in the Bovine Corpus Luteum as Characterized by Specific Monoclonal Antibodies."

Dr. Alila earned his Veterinary Degree from the University of Nairobi, Kenya in 1978. He is presently completing work towards a Ph.D degree in the area of Reproductive Physiology under the direction of Dr. William Hansel, Dr. Neil Norcross, Dr. Thomas Reimers and Dr. Katherine A. Houpt. The research for which he was cited involved the production of highly specific cell labels (monoclonal antibodies) by the use of genetic engineering techniques, and the use of these cell labels to trace the origins of all of the cells in the corpus luteum during the estrous cycle and throughout pregnancy. The corpus luteum is the endocrine body formed in the site of a ruptured ovarian follicle which produces the hormones responsible for estrous cycles and pregnancy maintenance. Several new concepts of how this organ functions arose from Dr. Alila's work and may ultimately lead to improved methods of fertility control.



Puppy, a Newfoundland owned by Jerry Letterei, was a familiar fixture at the College. Although large, quiet, and in later years slow, Puppy trained us to open doors, fetch water and respect privacy. Early in 1983, he underwent surgery to remove a tumor on his spleen. Unfortunately, the cancer spread, and Puppy died during the summer. We will miss our friend.



## FACELIFT

In recent months, the timeworn paddocks outside the large animal clinic have been replaced by 12 brand-new paddocks—nearly double the previous number. An additional improvement, two riding and lungeing rings were added at the west end of the paddock area for riding and exercising.

## TRAINING VETERINARY PATHOLOGISTS FOR AGING RESEARCH

The Department of Pathology, New York State College of Veterinary Medicine, Cornell University, in conjunction with the Cornell Medical College, NYC, was recently awarded a unique five-year training grant by the National Institute of Aging. The new program, entitled "Training Veterinary Pathologists for Aging Research", offers an unusual opportunity for veterinarians to develop an investigative career in the rapidly expanding field of aging research.

The program is specifically designed to provide a highly selective training program in aging research for veterinarians pursuing an academic career in biomedical research. Prerequisites include 1) enrollment in the graduate school of Cornell University; 2) at least one year of supervised residency training in veterinary pathology and 3) documentation of research interest and potential, particularly as it relates to the field of aging.

Candidates who have completed the prerequisite requirements will receive an additional three years of post-doctoral research

training. The first year, taken on the Ithaca campus, will emphasize disciplinary training in the pathology of laboratory animal species, appropriate graduate course work, and organization of the trainee's PhD thesis research project. The second and third years will emphasize the conduct and completion of a specific age-related research project associated with funded aging research programs being carried out at the Cornell Medical College in New York City.

Successful completion of the program will lead to a PhD in experimental pathology (Pathobiology of Aging) and eligibility for specialty board certification by the American College of Veterinary Pathologists. Stipend levels for candidates are dependent on background and experience as dictated by NIH guidelines. Additional information may be obtained by contacting Robert M. Lewis, DVM, Chairman of the Department of Pathology at the New York State College of Veterinary Medicine, Cornell University, Ithaca, NY, 14853.

## CALENDAR

November 12—Canine Symposium at the Hilton at Merrimack, Merrimack, New Hampshire. Faculty of the New York State College of Veterinary Medicine will speak on breeding, whelping and young dog care.

December 5-8—American Association of Equine Practitioners 29th Annual Convention, Las Vegas, Nevada. For information, contact: Dr. Wayne Kester, (303) 526-0820.

December 5—James Law Distinguished Lecturer Series, Dr. C. C. Wang, from the University of California at San Francisco, Medical School, speaking on the "Biochemical Approach to Parasite Chemotherapy." 4:30, James Law Auditorium.

January 10-12, 1984—Annual Veterinarians Conference at the New York State College of Veterinary Medicine, Cornell.

January 16-18—Eastern States Veterinary Conference, Orlando, Florida. Contact: Dr. Gene Cope, (904) 392-4847.

## FOOTNOTES

The Student Chapter of the American Association of Equine Practitioners at the New York State College of Veterinary Medicine has begun a newsletter for everyone interested in equine-related news at the College. The publication, called "Equine Rounds", will appear quarterly. To receive a copy, contact Geoffrey Tucker, Editor, Student Chapter, A.A.E.P., NYSCVM, Ithaca, NY, 14853.

Copies of the *Equine Research Report* of the New York State College of Veterinary Medicine are now available from the Office of Public Information, NYSCVM, Ithaca, NY, 14853.



## A HEADACHE FOR CATS

By Kenneth Marcella, DVM

Your cat shouldn't be caught dead with some of man's safest and most effective over-the-counter anti-pain medications. Over 200 of these human pain-reliever preparations contain the drug acetaminophen. Cats are so uniquely sensitive to this drug that as little as one regular strength tablet (325 mg.) may kill your feline friend.

The cat's initial reaction to acetaminophen is similar in some ways to human cyanide poisoning. In both cats and humans breathing becomes heavy. Then a person shows signs of headache, dizziness, nausea and drowsiness. Their difficult breathing becomes more severe and without treatment, the human victim begins to convulse. Death follows rapidly.

In the cat, as breathing becomes difficult, signs of suffocation appear. The animal's tongue and gums may turn a blue color (cyanosis) due to lack of oxygen. Cats will also vomit and may have a noticeable swelling of the head and neck. If untreated, these cats rapidly begin to convulse and then die. The similarities to cyanide poisoning in humans are obvious but the reasons for the similar signs are quite different.

Acetaminophen goes through a series of processing steps in the human body. Most of the drug is changed in chemical reactions that take place in the liver. The products of these reactions are quite harmless and are removed from the body by way of the kidneys and urine. A small percentage of the drug is not changed at all and also finds its way into the urine. Some of the drug is changed in still another chemical process. The result of this process is a new substance that is toxic to the body. Normally, this toxic metabolite is altered yet again by another enzyme, glutathione, and the resulting product is rendered harmless.

Cats, however, have very low levels of glutathione so they cannot detoxify the metabolites of acetaminophen. These metabolites alter feline red blood cells, changing the hemoglobin, the oxygen carrying compound of the blood cell, so that it can no longer transport oxygen. Cats with acetaminophen poisoning cannot breathe on a cellular level so they show signs of suffocation.

Humans with acetaminophen poisoning show very different signs from those of similarly poisoned cats. The toxic metabolites produced in humans do not attack hemoglobin to the same degree as in cats. Consequently, lack of oxygen and rapid death from suffocation is not seen. Instead, humans will initially show signs of sweating, nausea and vomiting. These will pass within twelve hours or so and the patient may appear normal. Within twenty-four hours, however, the human liver cells have been severely damaged on a cellular level. Signs of this destruction will become apparent over the next three to five days. The patient then becomes very ill, eventually enters a coma and death follows.

Treatment for acetaminophen toxicity in both humans and cats must begin as soon after ingestion of the medication as possible. The drug N-acetylcysteine is now commonly used as an effective treatment for this type of overdose in both species. N-acetylcysteine is a precursor or a building block for glutathione and this substance helps detoxify the dangerous metabolites of acetaminophen.

Time is the key factor. Clinical success and patient survival are directly related to the length of time between ingestion and treatment. The very rapid feline respiratory effects and the silent but deadly human



liver destruction occur so quickly that effective treatment should be started within eight to ten hours in humans and within four hours in cats. If cats survive the initial period, they often do very well and with appropriate supportive care will live healthy lives.

As with most medical problems, prevention is better than treatment and the key to prevention is owner education. Any form of aspirin or human pain reliever may be very dangerous to cats and should never be

given. When your pet needs pain relief or any type of medication, do not hesitate to contact your veterinarian. He or she will be happy to give you the best and safest medication for your pet's problem. Don't forget to take special precautions with medicine bottles around the home. Use child-proof caps and keep all medications in a cabinet out of reach of children and curious pets. Drugs and medications can have both life-saving and life-threatening effects. Your pet is counting on you to know the difference.

Veterinary  
Viewpoints

The New York State College of Veterinary Medicine  
Cornell University  
Ithaca, New York 14853

Nonprofit Org.  
U.S. Postage  
PAID  
Cornell  
University

NEW YORK STATE VETERINARY COLLEGE  
FOWLER LIBRARY  
CORNELL U., ITHACA, NY 14853